

Allied Health Media

OccupationalTherapy.com

If you are viewing this course as a recorded course after the live webinar, you can use the scroll bar at the bottom of the player window to pause and navigate the course.

Allied Health Media

OccupationalTherapy.com

This handout is for reference only. It may not include content identical to the powerpoint.

Any links included in the handout are current at the time of the live webinar, but are subject to change and may not be current at a later date..

Sensory Spinal Tracts

Andrew Persch, PhD, OTR/L, BCP

Presenter

Andrew C. Persch, PhD, OTR/L, BCP

Assistant Professor
Division of Occupational Therapy
The Ohio State University

andrew.persch@osumc.edu

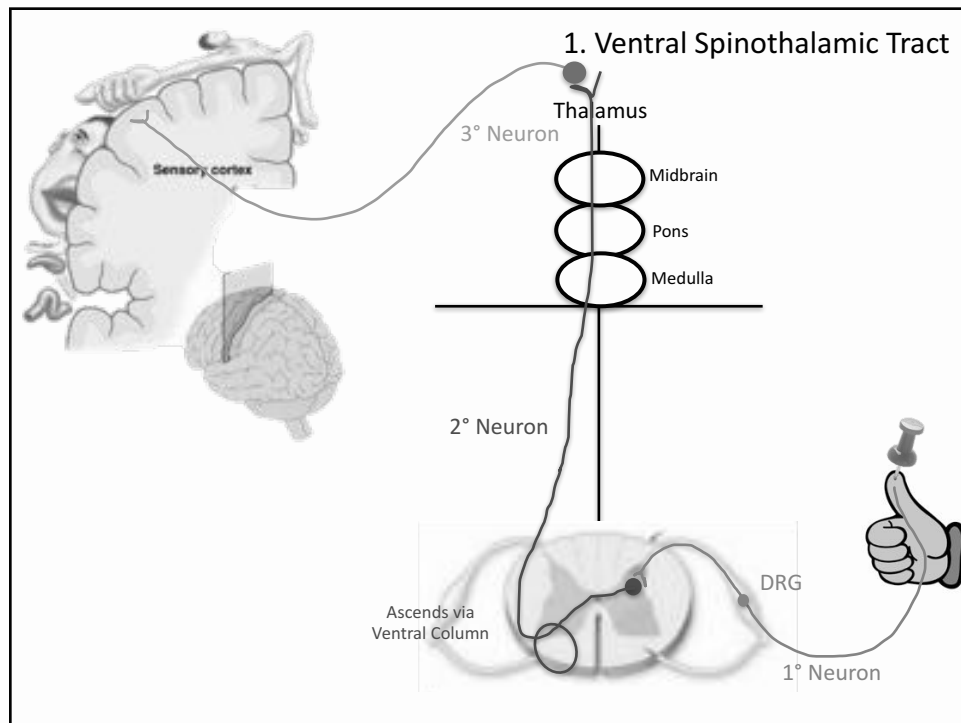


Learning Objectives

1. Define the neuroanatomical pathway of sensory tracts in the human nervous system.
2. Identify the functions of individual sensory tracts
3. Explain the functional relevance of individual sensory tracts to occupational therapy practice

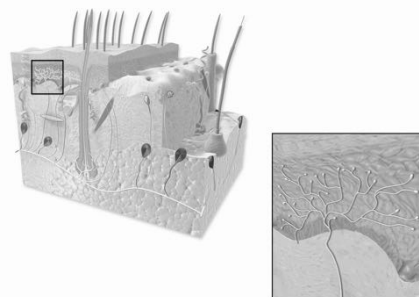
Agenda

Time	Topic
0-5	Introduction
5-15	Ventral Spinothalamic
15-25	Lateral Spinothalamic
25-35	Fasciculus Gracilis
35-45	Fasciculus Cuneatus
45-55	Spinocerebellar
55-60	Conclusion, Q and A, Summary



Ventral Spinothalamic Tract Overview

- Protopathic tract - protective sensory responses
 - Coarse touch – pressure, pleasant touch, tickle, itch
 - These fibers DO NOT do discrimination, touch localization, size or number of touchpoints
- Receptors = free nerve endings (FNE)
- Afferent fibers = C-Fibers



Free Nerve Endings

Ventral Spinothalamic Tract Overview

- 3-Neuron system
 - 1° neuron: FNE stimulated → Dorsal Horn of spinal cord
 - Nuclei in Dorsal Root Ganglion
 - 2° neuron: Dorsal horn of spinal cord → Thalamus
 - Crosses midline in gray matter at the level of the dermatome
 - Ascends spinal cord in anterior white matter (Ventral column)
 - 3° neuron: Thalamus → Sensory Cortex of brain
 - Projects through internal capsule of corona radiata into sensory cortex

Ventral Spinothalamic Tract: Case Study

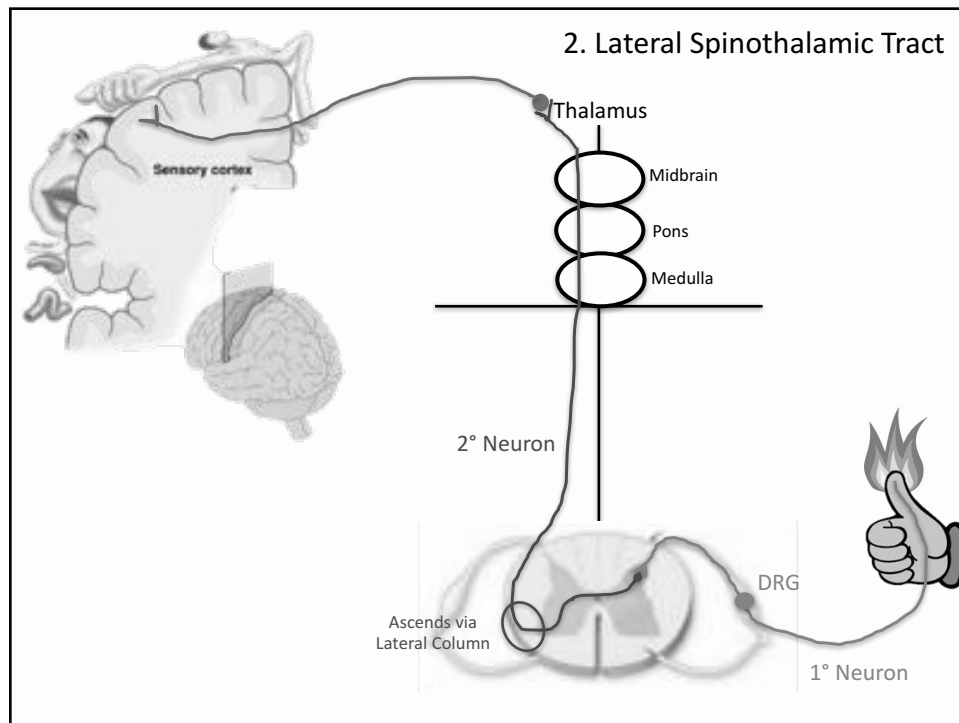
- Ruby is a 68 y.o. woman who lives with her husband in a 1 story home.
- She has two adult children who live outside of the home with spouses and children of their own.
- Every month, the whole family gathers together for a Sunday night dinner.
- Ruby prepares all of the food for these dinners, and it is a role that she greatly values.
- 3 weeks ago, at the most recent monthly dinner, Ruby sustained a deep partial thickness burn to her right (dominant) hand while removing a pot roast from the oven.
- She immediately went to the hospital, and is now seeing an occupational therapist at an outpatient hand clinic for range of motion, scar management, and sensory deficits.

Ventral Spinothalamic Tract: Case Study

- Evaluation
 - To assess Ruby's ventral spinothalamic pathway, you want to assess her coarse touch through a basic sensation screen.
 - Have her close both eyes and firmly press on each upper extremity at different locations (hands, forearm, upper arm). Have Ruby identify if she can feel the touch and which arm it is on (right or left)
 - In addition, sensory deficits can result in impairments in manual control. Therefore, fine-motor skills, such as those required for grasping and manipulating small objects, should be evaluated for this patient. (e.g. Box and Block test, 9-hole peg test, in-hand manipulation test)

Ventral Spinothalamic Tract: Case Study

- At this stage in her recovery, you will likely focus on sensory reeducation techniques
 - Provide pressure to affected hand to stimulate the nerves
 - Cue patient to observe affected area visually to reconnect the neural pathways to improve sensation
 - Functional sensation activities, i.e. place items such as small Emory boards (nail file), clothes pins, and feathers in bucket of rice. Therapist will have patient retrieve these items using their sensation to differentiate between different surfaces and tactile cues.



Lateral Spinothalamic Tract Overview

- Protopathic tract - "protective" sensory responses
 - Detects pain and temperature
- Two types of pathways:
 - Detecting Pain
 - Receptors = free nerve endings, nociceptors
 - Fibers = Fast pain: **AΔ** fibers, Slow pain: C fibers
 - Detecting Temperature
 - Receptors = free nerve endings
 - Fibers = Cold: **AΔ** fibers, Heat: C fibers

AΔ fibers: fast pain, cold
C fibers: slow pain, heat

Lateral Spinothalamic Tract Overview

- 3-Neuron System
 - 1° neuron: Primary sensory neuron (DRG) --> Dorsal horn of the gray matter
 - 2° neuron: Dorsal horn --> Thalamus
 - 3° neuron: Thalamus --> Sensory Cortex
 - Passes through white matter in-between cortex and the thalamus

Lateral Spinothalamic Tract: Case Study

- Jessie is a 6 y/o girl with hemiplegic cerebral palsy.
- She has been receiving occupational and physical therapy treatment since she was two years old to address motor deficits in her affected right side.
- She is now able to feed and dress herself independently, and she is now working on school-based goals.
- As she has gotten older, her parents noticed that she does not always respond to certain sensations on her right side.
- She often has scrapes on her right arm, and once she burned her hand under hot water from the sink because she didn't realize how hot it was.
- Her parents are concerned that as she continues to gain mobility and independence, she may cause serious harm to herself without realizing it.
- They mention this concern to their OT to see if she has any suggestions on what to do.

Lateral Spinothalamic Tract: Case Study

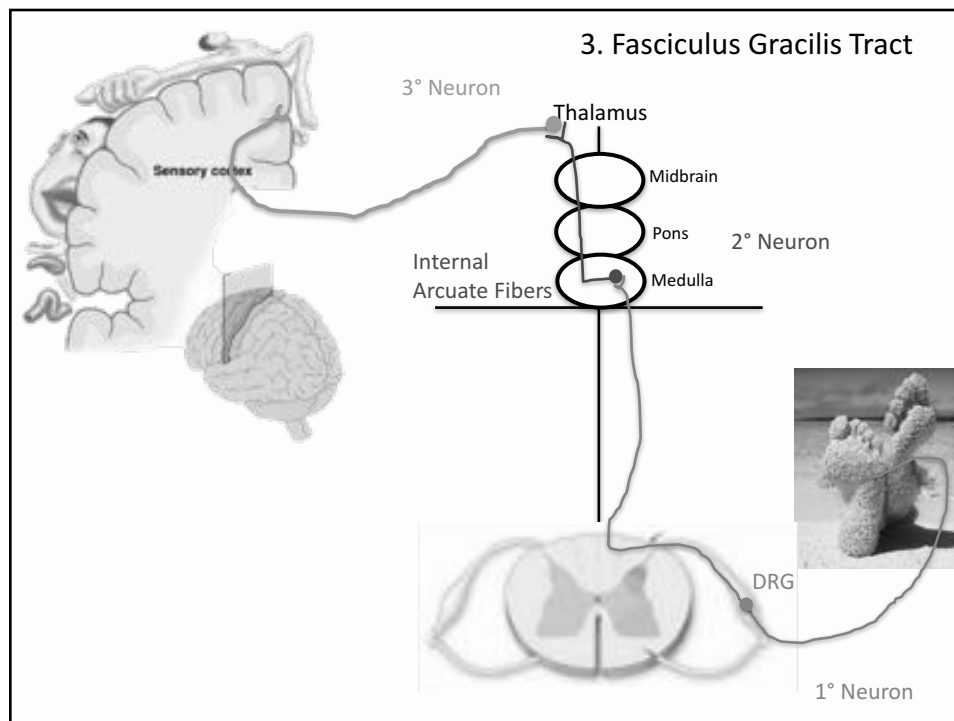
- Evaluation
 - Intact pain and temperature awareness are indicative of protective sensation, and thus, a working lateral spinothalamic tract.
 - If an individual does not respond to painful or hot stimuli, this tract may be impaired.
 - To test for pain (protective sensation): Use a sterilized safety pin and apply the appropriate amount of pressure to elicit a pain response on the child's non-affected hand. The therapist will then use this same amount of pressure to test for a protective pain sensation on the affected hand.
 - Alternate randomly between the sharp and dull sides of the safety pin and ask the patient to respond if the stimulus is "sharp" or "dull." A correct response to both sharp and dull stimuli indicates intact protective sensation. An incorrect response to both sharp and dull indicates an impairment in protective sensation.

Lateral Spinothalamic Tract: Case Study

- Evaluation Ctd.
 - In the clinic, it is important to test for temperature awareness before applying cold or heat modalities. To test for temperature awareness (protective sensation): apply test tubes filled with hot or cold fluids randomly to areas of the involved hand.
 - The patient should indicate "hot" or "cold" following application.
 - A correct response to both hot and cold indicates intact temperature awareness. An incorrect response to both hot and cold indicates an impairment in temperature awareness and protective sensation.

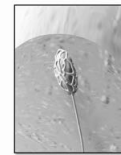

Lateral Spinothalamic Tract: Case Study

- Treatment
 - Individuals who lack protective sensation due to a damaged lateral spinothalamic tract are at a significant risk for serious injury due to their lack of perception of pain, heat, or cold.
 - Protective Sensory Re-Education:
 - Protect from being exposure to sharp items or those of extreme temperature
 - Use built-up handles, when possible, to distribute gripping pressure over a wider surface area.
 - Visually scan the skin for redness, irritation, blisters, edema, cuts, etc. This is especially important because tissue heals more slowly when nerve damage has occurred.
 - Do not continue the same activity for prolonged periods of time. Instead, take breaks and switch up tools and items that are held in the hand.



Fasciculus Gracilis Tract Overview

- Epicritic "discriminative" sensory
 - Same as Fasciculus Cuneatus Tract, but for LOWER EXTREMITY
- Receptors
 - Meissner's Corpuscle
 - Pacinian Corpuscle
 - Hair follicle free nerve endings
- Fibers = $A\beta$



Tactile Corpuscle
(Meissner's Corpuscle)

Fasciculus Gracilis Tract Overview

- 3-Neuron System
 - 1° neuron: Primary Sensory Neuron (DRG) and Medial Dorsal Column pathway (NOT dorsal horn)
 - Internal Arcuate Fibers in the Medulla
 - 2° neuron: Internal Arcuate Fibers in the Medulla
 - Ascends to Thalamus as Medial Lemniscus
 - 3° neuron: Medial Lemniscus in Thalamus → Sensory Cortex

Fasciculus Gracilis Tract Case Study

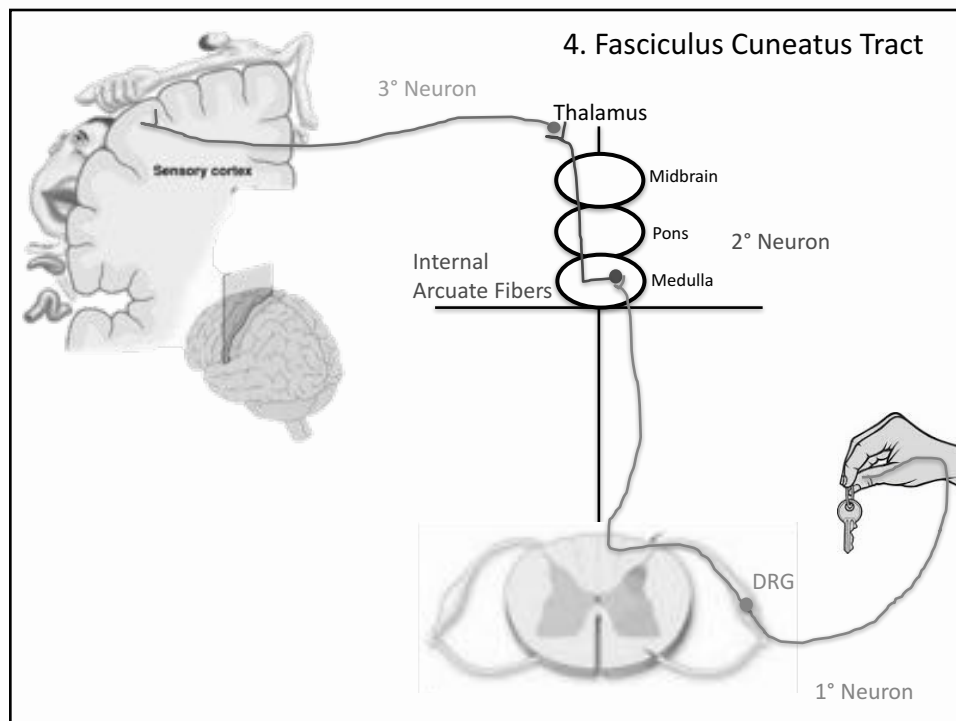
- Greg is a 35 y/o man who was recently diagnosed with relapsing-remitting multiple sclerosis.
- During periods of exacerbation, he experiences sensory loss in his hands and legs.
- He has a large backyard, and often walks around the yard when he lets his dog out each morning.
- Once when he tried to go out barefoot during an exacerbation, he was unable to tell when he stepped off of his concrete patio onto the grass.
- The lack of sensation also made it difficult to walk more than a few feet without stumbling.
- His doctor recommended that he bring this up with his outpatient OT.

Fasciculus Gracilis Tract Case Study

- Evaluation
 - Proprioception Screens: Have the patient first close his eyes. Then, move his knee into flexion or extension. Ask him to identify if his knee is “bent” or “straight” after the movement has taken place. Repeat this with the ankle and toes on each side of the body.
 - 2-Point Discrimination Testing: Have the patient close his eyes. Use a disk-criminator to touch the bottom of each toe. Test the patient with each set of prongs until they can no longer distinguish two unique points on 2/3 trials. Alternate starting with higher threshold prongs and lower threshold prongs. Repeat on each toe.

Fasciculus Gracilis Tract Case Study

- Treatment
 - Have the patient practice performing functional tasks while walking on different surfaces. Encourage them to visually scan the area for potential tripping hazards and terrain changes as they walk.
 - Educate the patient on simple home modifications they can make to increase their safety at home. Encourage the patient to wear slip-proof socks and slippers when walking on hardwood floors, decrease the pile of carpets.



Fasciculus Cuneatus Tract Overview

- Epicritic "discriminative" sensory
 - Fine touch; 2 point and vibration discriminative, conscious proprioception, stereognosis
 - Crosses the midline as internal arcuate fibers in the medulla and ascends contralaterally to the thalamus
- Receptors
 - Meissner's Corpuscle
 - Pacinian Corpuscle
 - Hair follicle free nerve endings
- Fibers = $A\beta$

Fasciculus Cuneatus Tract Overview

- 3-Neuron System
 - 1° neuron: Primary Sensory Neuron (DRG) and Lateral Dorsal Column pathway (NOT dorsal horn)
→ Internal Arcuate Fibers in the Medulla
 - 2° neuron: Internal Arcuate Fibers in the Medulla
→ Ascends to Thalamus as Medial Lemniscus
 - 3° neuron: Medial Lemniscus in Thalamus → Sensory Cortex

Fasciculus Cuneatus Tract Case Study

- Greg is a 35 y/o man who was recently diagnosed with relapsing-remitting multiple sclerosis.
- During periods of exacerbation, he experiences loss of sensation in his hands and legs.
- He works for a clothing company, and he often has trouble distinguishing the difference between various textures of fabric.
- He also notices that he has difficulty finding his keys in his briefcase by touch alone.
- His doctor recommended that he see an outpatient occupational therapist to learn more about his sensation problems and how to manage them at work.

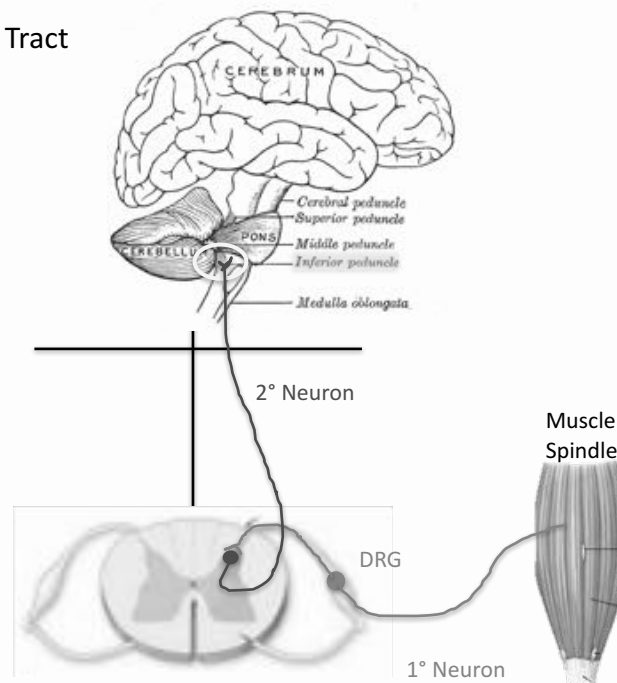
Fasciculus Cuneatus Tract Case Study

- Evaluation
 - Proprioception Screens: Have the patient first close his eyes. Then, move his elbow into flexion or extension. Ask him to identify if his elbow is “bent” or “straight” after the movement has taken place. Repeat this with the wrist and fingers on each side of the body.
 - 2-Point Discrimination Testing: Have the patient close his eyes. Use a disk-discriminator to touch the tip of each finger. Test the patient with each set of prongs until they can no longer distinguish two unique points on 2/3 trials. Alternate starting with higher threshold prongs and lower threshold prongs. Repeat on each fingertip.
 - Stereognosis Testing: You can use an official stereognosis testing kit, or gather household objects such as a key, coin, paperclip, etc. Place all objects in an open container. Have the patient close their eyes, pick up an object with one hand, and identify it using only touch.

Fasciculus Cuneatus Tract Case Study

- Treatment
 - Discriminative Sensory Re-Education
 - Have the patient search for specific objects in their briefcase or pocket
 - Compensatory Training
 - Train the patient to use eyesight as much as possible to identify objects.
 - Have the patient keep regularly used items, such as keys, alone in a specific pocket of their purse or briefcase, so they always know where to find them without needing to look.
 - If the sensation problem only exists on certain parts of their body, teach the patient to use other parts, such as upper arms or cheek, to identify different fabric textures.

5. Spinocerebellar Tract



Spinocerebellar Tract Overview

- Unconscious Proprioception
 - Unconscious adjustments to movement and posture
 - Essential for coordination as you move your body throughout space
- Receptors = Golgi Tendon Organs (GTOs) in muscles that are sensitive to pressure OR Muscle Spindles which are sensitive to stretch.
- 2-Neuron system
 - 1° neuron: Primary sensory neuron (DRG) → Dorsal horn of the spinal cord
 - Nuclei in Dorsal Root Ganglion
 - 2° neuron: Dorsal horn of spinal cord → Inferior Cerebellar Peduncle (ICP)
 - The tract enters the cerebellum via the ICP

Spinocerebellar Tract: Case Study

- Joe is a 45 y/o man who works for a moving company for the past 10 years.
- He spends most of his days lifting and moving heavy furniture.
- Joe recently went to the doctor due to persistent dull pain and tingling in his buttocks and lower limbs.
- He also reported feeling weak and unsteady on his feet, often stumbling or bumping into things during demanding work days.
- The doctor told Joe he has a herniated disc, which may be placing pressure on his spinocerebellar tract and resulting in decreased proprioception in his lower limbs.
- He was referred to outpatient PT and OT for further assessment.

Spinocerebellar Tract: Case Study

- Evaluation
 - To assess Joe's spinocerebellar tract and proprioception, have him first close his eyes. Then, move Joe's knee into flexion or extension. Ask Joe to identify if his knee is "bent" or "straight" after the movement has taken place. Repeat this test with his ankle.
 - Observe Joe's posture as he stands and walks during functional tasks. Observe if he is unsteady on his feet, if he is slow to correct his posture, and how frequently he bumps into things.

Spinocerebellar Tract: Case Study

- Treatment
 - The spinocerebellar tract involves unconscious proprioception; therefore, the therapist can work with Joe to bring greater awareness and attention to his body's position in space.
 - Have Joe perform tasks, such as carrying lightweight objects while watching himself in a mirror. Offer Joe verbal and tactile cues to correct his posture when he becomes more unsteady.
 - Teach Joe proper body mechanic principles in order to prevent worsening of his current symptoms.

QUESTIONS?