- If you are viewing this course as a recorded course after the live webinar, you can use the scroll bar at the bottom of the player window to pause and navigate the course.

- This handout is for reference only. Non-essential images have been removed for your convenience. Any links included in the handout are current at the time of the live webinar, but are subject to change and may not be current at a later date.

CONTINUED

Technical issues with the Recording?

- Clear browser cache using these instructions
- Switch to another browser
- Use a hardwired Internet connection
- Restart your computer/device

Still having issues?

- Call 866-782-9924 (M-F, 8 AM-8 PM ET)
- Email customerservice@OccupationalTherapy.com

CONTINUED

Examination and Assessment of the Upper Extremity

Valeri Calhoun MS, OTR/L, CHT
Saint Louis, Missouri

1

CONTINUED

Description

- This is a two course series that will provide clinical assessment tools and guidelines to aid in the treatment planning for the upper extremity involved patient.

2

CONTINUED

Learning Outcomes

As a result of this course, participants will be able to:

1) Define 3 primary upper extremity components to address for a comprehensive upper extremity examination

2) List 2 pain and outcome tools

3) List 2 components of wound care assessment

4) List 2 components of scar and edema assessment

3

CONTINUED

Why is an Evaluation Necessary

- Establish baselines
- Determine components to be addressed in treatment/establish treatment plan
- Determine limitations
- Establish treatment goals
- Determine treatment results and outcomes
- Efficacy of treatment

4

CONTINUED

What Do Examination Methods Need?

- Accurate
- Standard methods
- Reliable
- Reproducible
- Valid
- Needs to be meaningful to your outcome

5

CONTINUED

Documentation:

- Concise
- Clear
- Accurate
- Measureable
- Photographs
- Electronic: format
  - Pros
  - Cons

6

CONTINUED

Evaluation:

- Evaluation = observation + subjective + examination + conclusion + recommendations
- Need a systematic examination process

7

CONTINUED

Screening: Subjective

- Personal Information: Age, hand dominance, occupation, hobbies, medications
- History:
  - Date of injury, surgery
  - Onset of symptoms
  - Diagnostics performed
  - Previous treatment

8

CONTINUED

Subjective:

- Full medical history:
  - Other conditions or illnesses
  - Alcohol or tobacco use
  - Nutrition

9

CONTINUED

Subjective:

- Functional limitations:
  - ADLs
  - Work
  - Hobbies
  - School activities
  - Sports
- Have them keep a journal if unsure.

10

CONTINUED

Subjective:

- Symptoms (objectify):
  - Pain, numbness tingling, weakness, deformity, impaired coordination
    - When
    - Duration
    - Where
    - Interfere with activity
    - Interfere with sleep

11

CONTINUED

Subjective:

- Patient Goal of treatment
  - Return to work
  - Return to sport
  - Perform ADL/specific activity

12

CONTINUED

Subjective: History

- Complete once you understand the impact this condition has on the patient
  - Psychologically
  - Physically
  - Socially
  - Economically

13

CONTINUED

Pain

- Pain Reports: Intensity
  - Verbal analog scale: 0-10
  - Least/worst rating
  - Duration, frequency, consistency
  - Location
  - Exacerbating/alleviating factors

14

CONTINUED

Pain

- Pain charts
  - Visual analog scale (VAS)
  - Wong Baker Faces scale
  - Observational pain rating
  - Pain drawings

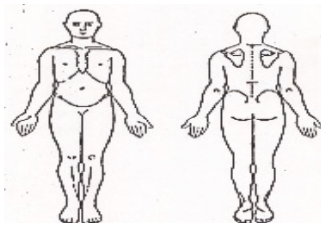

15

CONTINUED

Pain

- What makes it better?
  - Rest
  - Ice
  - Position
  - Medication
- What makes it worse?
  - Use
  - Specific activity
  - Position
  - Force

16

CONTINUED

Patient Rating Scales: symptom or satisfaction ratings

- Self Reported Health Related Outcome Measures
  - Age specific
  - Condition specific
  - Region specific
  - Global measures

17

CONTINUED

Patient Rating Scales: Symptom or Satisfaction Ratings

- DASH: Disabilities of the Arm, Shoulder and Hand
- Patient Rated Wrist/Hand Evaluation (PRWHE)
- PODCI

18

CONTINUED

Patient Rating Scales: Symptom or Satisfaction Ratings

- DASH
  - 30 components
  - ADL Performance and symptoms
- Quick DASH
  - 11 components derived from original DASH
- MAYO
  - Elbow and wrist separate evaluation scales
  - Pain, function, motion, strength
- Oxford
  - Pain and function
  - Shoulder and Elbow



19

CONTINUED

Patient Rating Scales: Symptom or Satisfaction Ratings

- Patient-Rated Wrist Evaluation (PRWE)
  - Measures pain & disability in patients with wrist pathology
  - High test-retest reliability
- UEFS
  - measures effect of UE disorders on function
- Michigan Hand Questionnaire
  - 37 items looking at health domains in patients with hand disorders
- ASES Elbow Form
  - Pain and function questions
  - High reliability and validity
- ASES Shoulder Form
  - Pain and function questions
  - High reliability and internal consistency

20

CONTINUED

Objective: Observation screen

- Physical Findings : visual edema, color, skin condition
- Movement: Tremors, atrophy, ischemic contractures

21

CONTINUED

Observation:

- Wrinkles
- Calluses
- Atrophy

22

CONTINUED

Physical Description

- Deformity
- Arthritic Nodes:
  - –Heberdens' (DIP)
  - –Bouchard's (PIP)
- Resting joint postures



CONTINUED

Resting Posture:

24

CONTINUED

Sympathetic function

- Assessed through Observation and Palpation
- Sudomotor: sweating
- Vasomotor: skin color and temp.
- Pilomotor: gooseflesh response
- Trophic: skin texture, soft tissue atrophy ('penciling' of finger tips),nail changes, hair growth, rate of healing

Skirven, Osterman, Fedorczyk, Amadio, Rehabilitation of the Hand and Upper Extremity, sixth edition.

CONTINUED

Wound

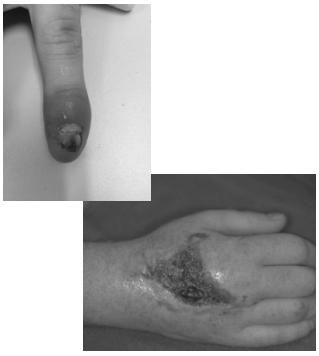

- Location
- Size: length, width, depth
- Color: red, yellow, black
- Odor: pungent, musty, sweet
- Temperature
- Integrity: tunneling, undermining, sinus tracts
- Drainage: sanguinous, serosanguinous, serous, purulent, foul purulent

CONTINUED

Wound

- Tissue: slough, eschar, granulation, macerated, dessicated, necrotic
- Wound edges: defined, attached
- Signs of infection: pain, redness, streaking, warmth, pus, fever

CONTINUED

Scar

- Location
  - Cross joints
- Size
- Rigidity
- Raised
- Palpate: Tender

28

CONTINUED

Scar

- Scar Description: red, raised, mature, immature, keloid, hypertrophic, supple, adherent

Vancouver Scar Scale: Burns
Pigmentation
Vascularity
Pliability
Height

CONTINUED

Vascular: Observation

- PALE: may indicate arterial insufficiency
- RED: may indicate infection/irritability
- CYANOTIC: may indicate venous insufficiency due to decreased circulation

CONTINUED

Vascular

- Assess pulses
  - Subclavian – sternal end of clavicle in scalene (mm.)
  - Axillary – center of armpit.
  - Brachial- superior to antecubital fossa, medial to biceps tendon.
  - Radial- just proximal to wrist crease, volar-radial wrist.
  - Ulnar – just proximal to wrist crease, volar-ulnar wrist.
- Capillary refill test: apply pressure to pulp of nail, N= 3 sec.

CONTINUED

Allen's Test for radial or ulnar arterial patency

- Palpate radial and ulnar arteries at the wrist, and apply pressure to occlude both.
- Exsanguinate the hand by having the patient open and close fist several times, then open the hand to a relaxed open position.
- Release one of the arteries
  - Note quality and time for the hand to re-perfuse.
  - Normal is 3-5 seconds.

(The hand: Anatomy, examination, and diagnosis, 4th Edition. (2011). In Rayan & Akelman (Eds.),*The American society for surgery of the hand.* Philadelphia: Wolters Kluwer/Lippencott Wilkens & Williams.)

33

Edema

- Observation: Creases, wrinkles, ROM, resting joint position
- Define: Brawny, pitting, location

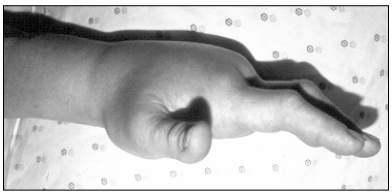

CONTINUED

Volumeter

- Evaluates hand mass via water displacement.
- Preferred method for edema measurement
- Mild difference from right to left hand (~3%), test both hands, but compare injured extremity to itself.
- Standard test

CONTINUED

Edema - Circumference

- Use flexible tape to measure in mm.
- Due to the variables of placement of tape and tension applied, this testing is not standardized or reliable.



- Common sites to measure:
  - P1, P2, and P3
  - PIP and DIP
  - Across MPs
  - Distal palmar crease (DPC)
  - Wrist level (DWC)
  - Elbow

CONTINUED

Figure of Eight

- Reliable method with high correlation between volumeter and figure of 8
- Four landmarks are used and provide a final number in cm
  1. Begin at distal aspect of ulnar styloid, cross volar wrist to distal aspect of radial styloid
  2. Diagonally across dorsal aspect of hand to 5th MCP jt.
  3. Volarly across level of DPC
  4. Tape is taken dorsally across the hand to the starting point at pisiform
- Sensitivity 99% Specificity 99%

CONTINUED

Thank you

- The second part is 8/27/19.
- Will cover the physical assessment and summarize the evaluation.

38

CONTINUED

References

- *Clinical assessment recommendations*, 3rd edition. (2015). American Society of Hand Therapists.
- Dutton Mark: orthopedic Examination, Evaluation & Intervention. McGraw Hill 2004
- Hislop, H., Montgomery, J., Daniels and Worthingham's Muscle Testing, 6th edition, W. B. Saunders Co., 1995
- Hunter, Mackin, Callahan; Rehabilitation of the Hand, 5th edition, Mosby
- Lavelle, K., & Stanton, D. (2013). Measurement of edema in the hand clinic. *Clinical assessment recommendations, 3rd edition.* Retrieved from https://www.asht.org/practice/clinical-assessment-recommendations

CONTINUED

References:

- Magee, D. J. (1997). Orthopedic physical assessment, 3rd Edition. Philadelphia: WB Saunders Co.
- McQuiddy, V. A., Scheerer, C. R., Lavalley, R., McGrath, T., & Lin, L. (2015. Normative values for grip and pinch strength for 6- to 19-year-olds. *Arch Phys Med Rehabil., 96*(9), 1627-33.
- Shechtman, O., & Sindhu, B. (2013). Grip strength. *Clinical assessment recommendations*. Retrieved from https://www.asht.org/practice/clinical-assessment-recommendations
- Skirven, T. M., Osterman, A. L., Fedorczyk, J.,& Amadio, P. C. (2011). *Rehabilitation of the hand and upper extremity*, Sixth Edition. (Chapters 6, 7,11, 12, 18). Amsterdam, Netherlands: Elsevier.

CONTINUED

References

- Sullivan, T., Smith, J., Kermode, J., et al. (1990). Rating the burn scar. *J Burn Care Rehabil,11, 256-60*.
- The hand: Anatomy, examination, and diagnosis, 4th Edition. (2011). In Rayan & Akelman (Eds.),*The American society for surgery of the hand.* Philadelphia: Wolters Kluwer/ Lippencott Wilkens & Williams.

CONTINUED

Questions?

- rvcalhoun@sbcglobal.net

42