

- If you are viewing this course as a recorded course after the live webinar, you can use the scroll bar at the bottom of the player window to pause and navigate the course.
- This handout is for reference only. Non-essential images have been removed for your convenience. Any links included in the handout are current at the time of the live webinar, but are subject to change and may not be current at a later date.

No part of the materials available through the continued.com site may be copied, photocopied, reproduced, translated or reduced to any electronic medium or machine-readable form, in whole or in part, without prior written consent of continued.com, LLC. Any other reproduction in any form without such written permission is prohibited. All materials contained on this site are protected by United States copyright law and may not be reproduced, distributed, transmitted, displayed, published or broadcast without the prior written permission of continued.com, LLC. Users must not access or use for any commercial purposes any part of the site or any services or materials available through the site.

Technical issues with the Recording?

- Clear browser cache using [these instructions](#)
- Switch to another browser
- Use a hardwired Internet connection
- Restart your computer/device

Still having issues?

- Call 866-782-9924 (M-F, 8 AM-8 PM ET)
- Email customerservice@OccupationalTherapy.com

continued[®]

Upper Extremity Rehabilitation for Traumatic Brachial Plexus Injuries

Anna VanVoorhis Miller, MS, OTR/L, CHT

2/6/20

continued[®]

Learning Outcomes

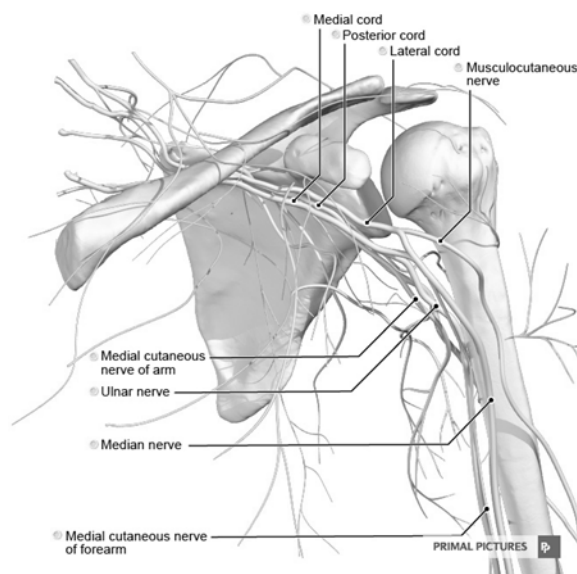
After this course, participants will be able to:

- Describe the anatomy of the brachial plexus and surrounding structures that may be affected by injury
- Identify and prioritize components of evaluation in brachial plexus injury.
- List rehabilitation approaches and techniques that are beneficial when working with patients with brachial plexus injury.

continued[®]

Introduction to the Brachial Plexus

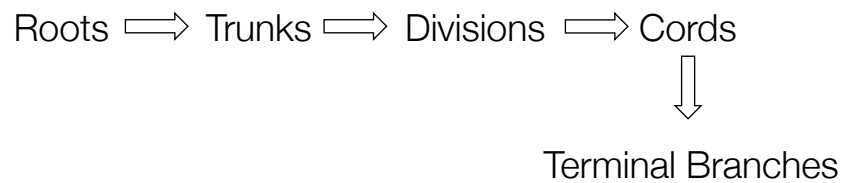
- The group of nerves that originate from spinal segmental levels C5-T1
- Responsible for animation and sensation of the entire upper extremity, shoulder to hand
- Injuries to the brachial plexus may impact part or all of the movement and sensation in the upper extremity



continued

The “Plexus Roadmap”

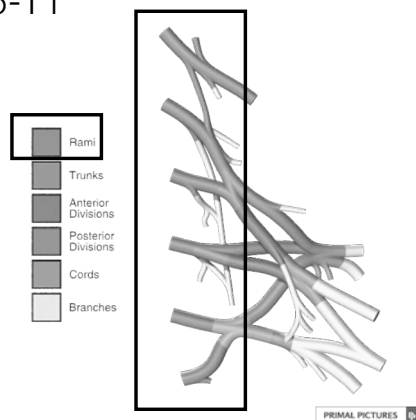
Although very complex, the brachial plexus can be broken down from **proximal** to **distal** in the following manner:



continued

Roots

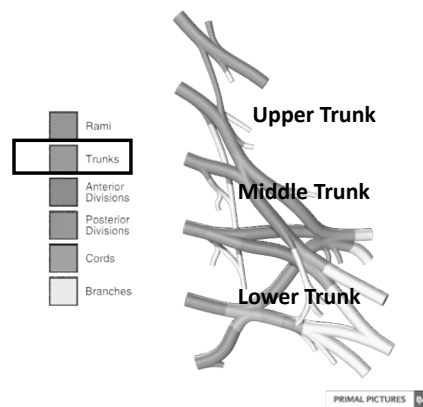
- Refers to nerve roots as they exit from spinal levels C5-T1



continued

continued

Trunks



continued

Trunks

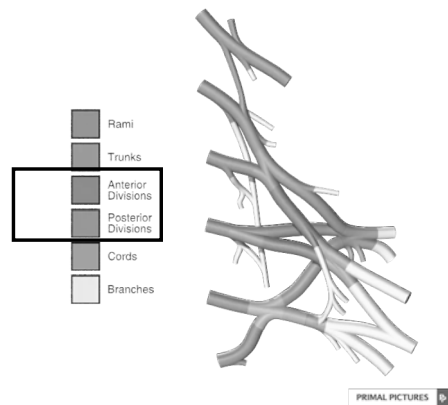
- **Upper: Contributions from C5,6**
 - Supplies suprascapular nerve, musculocutaneous nerve, and partial median nerve power. Disruption results in weak or absent shoulder abduction, external rotation, and elbow flexion
- **Middle: Contribution from C7**
 - Disruption causes weakness in ulnar wrist extension (extensor carpi ulnaris), triceps, wrist flexion, and finger extension
- **Lower: Contributions from C8, T1**
 - Supplies ulnar nerve and median nerve. Disruption results in weak or absent intrinsic function, finger flexion, and thenar function

(*Q1)

continued

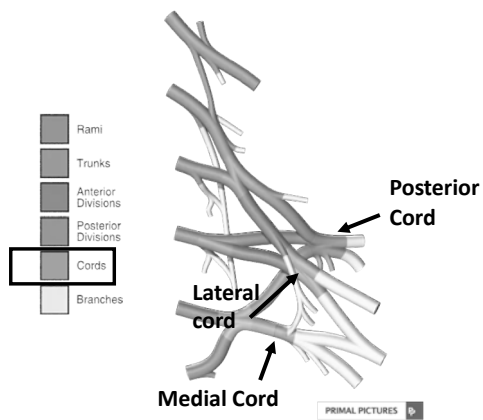
continued

Divisions



continued

Cords



continued

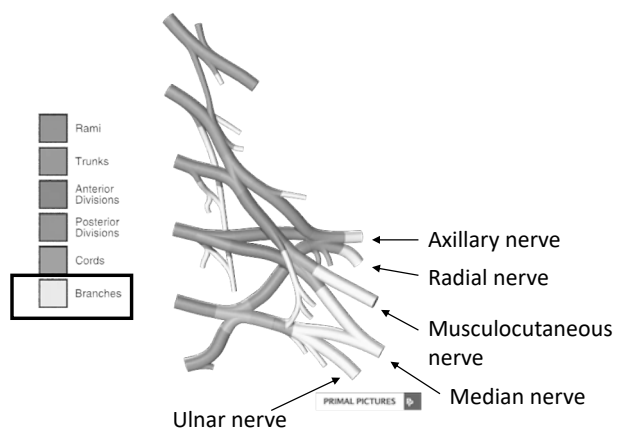
CONTINUED

Cords

- Lateral
 - Receives contribution from spinal levels C5, C6, C7
 - Supplies innervation to the lateral pectoral nerve, musculocutaneous nerve, and part of the median nerve
- Medial
 - Receives contribution from spinal levels C8, T1
 - Supplies innervation to the medial pectoral nerve, ulnar nerve, and part of the median nerve (with lateral cord)
- Posterior
 - Receives contributions from all spinal levels of the brachial plexus.
 - Supplies innervation to the rotator cuff muscles, latissimus, and all radial nerve-innervated muscles

CONTINUED

Terminal Branches



CONTINUED

continued

Traumatic Brachial Plexus Injury (BPI) in Adults

- Typically the result of high-velocity or high-impact
 - 31% motorcycle collision
 - 23% motor vehicle collision
 - 13% firearm injuries
- 21% of injured patients also tested positive for alcohol upon hospital admission
- 82% male
- Incidence data limited in US, but Canada estimates BPI accounts for 1.2% of all hospital admissions

(Prsic et al., 2019)

continued

Traumatic BPI, continued

- Aftermath of injury is often functionally devastating, can lead to a complete or partial loss of function and sensation
- Recovery can take up to 5 years and multiple surgeries
- Although advancements in surgical interventions have improved functional outcomes, many individuals with BPI have ongoing and complex psychosocial needs (Dodakundi, 2013)

continued

Classifying BPI

- Preganglionic:
 - Avulsion proximal to dorsal root ganglion-Poor prognosis due to involvement of CNS
 - **“Pan plexus injury”** = preganglionic avulsion/involvement of all nerve root levels
 - Current gold standard of diagnosis via CT myelogram and MRI (Karaliga et al., 2016)

(<https://www.orthobullets.com/trauma/1008/brachial-plexus-injuries>)

(*Q2)

continued

Classifying BPI, continued

- Postganglionic:
 - Avulsion distal to dorsal root ganglion
 - Involvement of PNS vs CNS
 - Improved prognosis; regeneration possible
 - Most firearm-related BPI are postganglionic due to penetrating nature of injury vs. stretch

(<https://www.orthobullets.com/trauma/1008/brachial-plexus-injuries>)

continued

continued

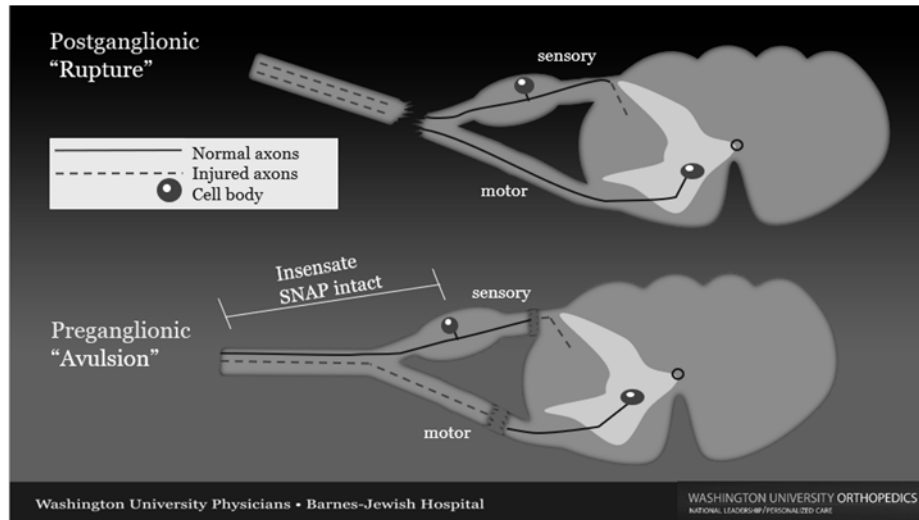
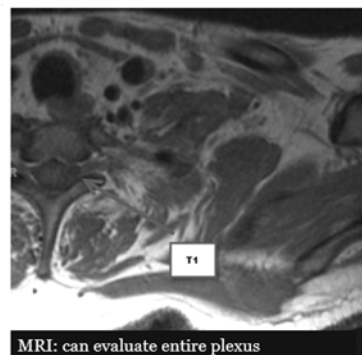
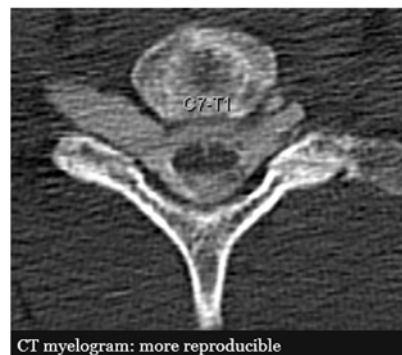

Photo courtesy of Dr. Christopher Dy of Washington University in St. Louis

continued



VS



Similar performance characteristics, but institution dependent
Surgeon preference

WASHINGTON UNIVERSITY ORTHOPEDICS
NATIONAL LEADERSHIP PERSONALIZED CARE

nerveresearch.wustl.edu | @ChrisDyMD

Photo courtesy of Dr. Christopher Dy of Washington University in St. Louis

continued

Nerve Transfers: When and Why?

- Direct repair and grafting are not viable options
- Long distance from lesion to target muscle
 - Proximal lesion, distal muscle
 - Reduces time of re-innervation
- Ability to utilize synergistic co-contraction of donor to recipient
 - Example: wrist flexion with elbow flexion in an FCU to biceps (double fascicular) nerve transfer
- Must be performed in a timely manner to preserve health of target muscle

(Dahlin & Wiberg, 2017)

Wallerian Degeneration

- Process of axonal degeneration that occurs immediately following injury
 - Affects segment of nerve distal to lesion
- Time of injury sets the “clock”
 - Timeframe to muscle death and fatty infiltration
- Typically will observe for signs of recovery up to three months prior to exploration
 - Although timeline varies in the literature

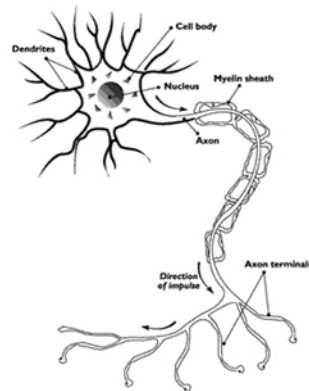


https://commons.wikimedia.org/wiki/File:Cartoon_Clock_Head_Man.svg

(Dahlin & Wiberg, 2017)

continued

Common Nerve Transfers

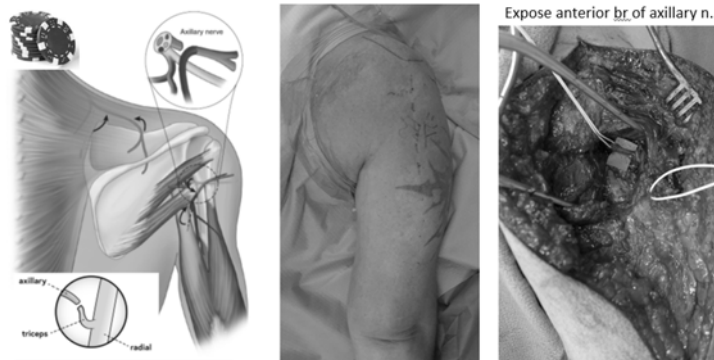


<https://commons.wikimedia.org/wiki/File:Nerve.nida.jpg>

continued

Triceps to Axillary

- Restores shoulder abduction via transfer of medial triceps to anterior branch of axillary nerve



WASHINGTON UNIVERSITY ORTHOPEDICS
RUTHMAN, LEONARD & PERSONALIZED CARE

nerveresearch.wustl.edu | @ChrisDyMD

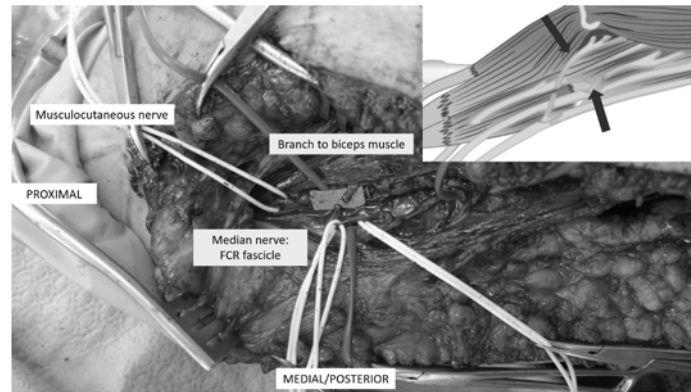
(*Q3) Photo courtesy of Dr. Christopher Dy of Washington University in St. Louis

continued

continued

Double Fascicular

- Restores elbow flexion: ulnar nerve fascicle to FCU + Median Nerve Fascicle to FCR, FDS transferred to musculocutaneous (Ray & Mackinnon, 2010)



(*Q4)

Photo courtesy of Dr. Christopher Dy of Washington University

continued

Brachialis to AIN

- Restores Median finger and thumb flexion via transfer of fascicles of Brachialis to the Anterior Interosseous nerve (Ray & Mackinnon, 2010)



Video courtesy of Lorna Kahn, PT, CHT

continued

continued

FCR to PIN

- Restores finger and thumb extension via transfer of fascicles from FCR to the Posterior Interosseous branch of the Radial nerve (Ray & Mackinnon, 2010)



continued

Evaluation of Brachial Plexus Injuries

- Not isolated to initial visit
- Ongoing and fluid process of evaluation and re-evaluation
- Encompasses biomechanical and psychosocial aspects of injury and recovery
- Ideally performed with an **interdisciplinary team**

(Janssen et al., 2019)

continued

continued

Team Approach to Care after BPI



Photo courtesy of Dr. Christopher Dy of Washington University

continued

Evaluation Priorities

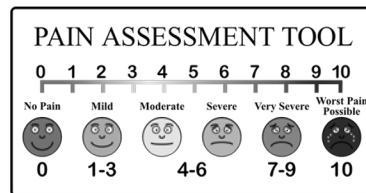
- History
 - Cause of injury
 - Timeline
 - Social support
 - Work history
 - Meaningful occupations
 - Goals
 - *Allows you to establish rapport*

continued

Evaluation Priorities, cont.

- Pain

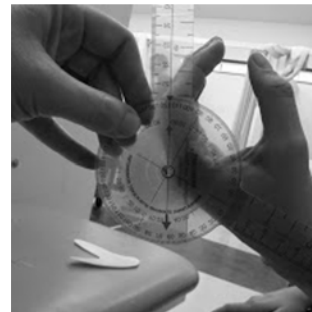
- 69% of patients with BPI reported some level of pain that impacted quality of life (Ciaramitaro et al., 2017)
- Record quality of pain based on subjective description (i.e. burning, stabbing, tingling, etc.)
- Exacerbating activities/positions
- Visual Analog Scale (0-10); high reliability in assessing acute pain (Bijur et al., 2008)



<https://freessvg.org/pain-scale-vector-clip-art>

Evaluation Priorities, cont.

- Range of motion
 - Available active
 - Passive range of joints without or with limited active movement
- Sensation
 - Semmes Weinstein Monofilament
 - Two point discrimination
 - Ten test (if time constraint or hypersensitivity prevent objective assessment)



https://commons.wikimedia.org/wiki/File:Goniometer_measurements.jpg

(*Q5)

continued

Manual Muscle Testing

- Should be thorough enough to involve the entire upper extremity and scapular muscles
 - Can help detect level of lesion (i.e. trunk, cord) or mixed-pattern type injury
- High level of reliability *if* the rater has a strong understanding of anatomy and testing procedure
 - Especially challenging with intrinsic musculature
(Brandsma et al., 1995)
- Should occur at initial eval. and monthly to track recovery

continued

Muscle Grades

- 0 No contraction or trace palpable
- 1 Trace contraction observed or felt, no motion
- 2 Joint moves through complete ROM with gravity minimized
- 3- Part moves through more than 50% of available ROM against gravity
- 3 **Part moves through complete ROM against gravity**
- 4 Part moves through complete ROM against gravity with resistance
- 5 Complete ROM and maximal resistance

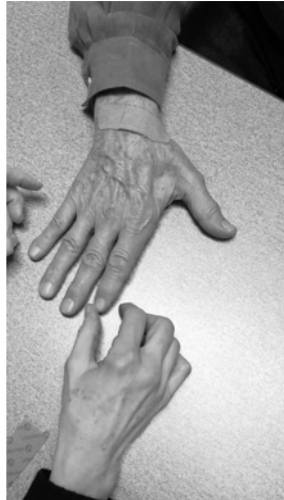(*Q6)

(Pendleton & Schultz-Krohn, 2006)

continued

continued

Manual Muscle Testing



Video courtesy of Lorna Kahn, PT, CHT

continued

Psychosocial Needs in BPI

- Review of 1,843 BPI patients with private insurance from 2007 to 2013 found that 54% had been diagnosed with anxiety or depression (Yannascoli et al., 2018)
- Greater risk than the general patient population for suicidal ideation and PTSD (Landers et al., 2017)
- Role changes, altered body image, and loss of supportive relationships common (Franzblau & Chung, 2015)
 - Only 17% were able to return to previously held job

continued

How do we incorporate into assessment?

- Per recent survey of OTs and CHTs, only 17.2% administered psychosocial assessments or made referrals to a mental health professional (Chown et al., 2018)
- Assessments such as the PTSD, Beck Depression Inventory, SF-36, and COPM can be implemented to gain a clearer understanding
 - Assist in making appropriate referrals to counseling, social work, and mental health professionals
 - **Interdisciplinary care**

continued

Impact of Brachial Plexus Injury Questionnaire

- In 2018 Mancuso and colleagues developed a BPI specific questionnaire (Mancuso et al., 2018)
 - measures physical and psychological impact of injury

Sample questions:

“Because of your brachial plexus injury, how much have you....”

1. Cut back on activities with family and friends
2. Had difficulty coping with arm situation
3. Thought you would be better off if your arm were amputated

continued

Do NOT feel pressure to get through everything at initial visit!!

- Goal is to set a few priorities, establish rapport
- Allow time for patient to speak freely as it happens, they have been through a lot!
- Try to explain rationale for evaluation components as you go along
- Work with your patient to establish a plan for the next visit, keep home program as simple as possible initially

continued

Treatment Approach

You've made it through the initial eval, what now?

- The type of injury or surgery will guide your treatment plan
 - Postganglionic injury, awaiting recovery: monitor and maintain
 - Preganglionic injury: maintain, pain management and positioning
 - Post op (repair, graft, nerve transfer): maintain, strengthen when appropriate, motor re-education

Donor Activation Focused Rehabilitation Approach (DAFRA)

- Guiding principles for motor re-education following nerve transfers
 - Focus on altered neural pathways, increase cortical plasticity
 - Patient education/understanding central to motor re-education
 - “Flood the donor”: maximize new neural pathways by “flooding” the donor muscle with low-load, high repetition exercise

(Kahn & Moore, 2016)

DAFRA, continued

3 Phases of treatment:

1. Early
 - Education on anatomy, transfer, and timeline for recovery
 - Establish a home program for donor activation
2. Middle
 - Monitor for signs of recovery
 - Advance home program to active-assisted exercise (“place and hold”)
3. Late
 - Resisted exercise (weights, bands once 3/5 strength achieved)
 - Biofeedback for motor re-education (Sturma et al., 2018)

(Kahn & Moore, 2016)

continued

Motor re-education

- Emphasis on combined donor contraction with concurrent recipient action
 - Active donor + passive recipient (Early Phase)
 - Bilateral exercise as much as possible
 - Use of gripping aids/orthoses to modify as needed
- Avoid resistance/high intensity in early phase
 - Can actually slow axonal regeneration
- “Brain training”

(*Q7)

(Kahn & Moore, 2016)

continued

Donor Strengthening

Example: use of “Active Hands” gripping aids to strengthen the brachialis following brachialis to AIN transfer

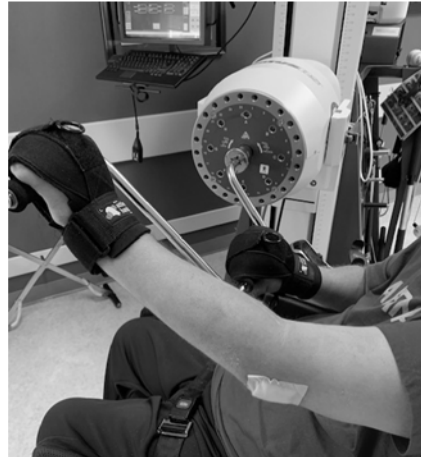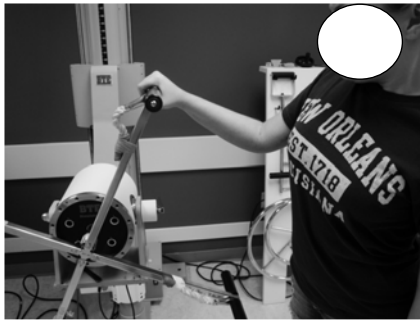- Gripping aids simulate finger flexion
- Can also be sewn with neoprene material



continued

continued

Donor Strengthening: BTE

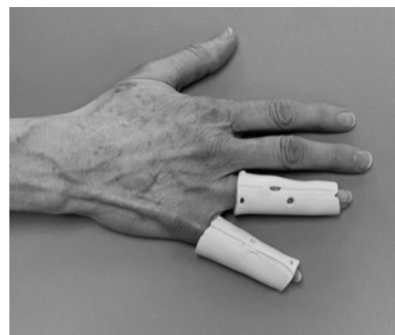


continued

Orthoses to Promote Motor Re-Education

Example:

The use of finger tube splints to prevent clawing while awaiting return of intrinsic function



(*Q8)

continued

continued

Orthoses to Promote Motor Re-Education

Example:




The use of an Oval-8 orthosis to prevent thumb IP hyperextension while awaiting recovery of flexion following brachialis to AIN transfer

(*Q9)

continued

Orthoses to Promote Motor Re-Education

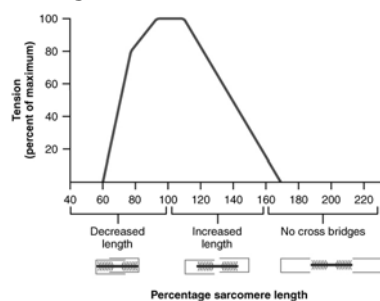
Example: Dynamic orthosis to resist wrist flexion and provide active assistance to finger extension following FCR to PIN transfer



continued

Length-Tension Relationship

- Denervated muscles often become overstretched/overshortened (Kahn & Moore, 2016)
 - Unopposed force of antagonist
 - Faulty movement patterns
 - Poor positioning



https://commons.wikimedia.org/wiki/File:1011_Muscle_Length_and_Tension.jpg

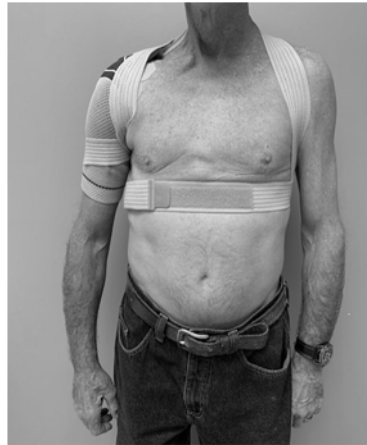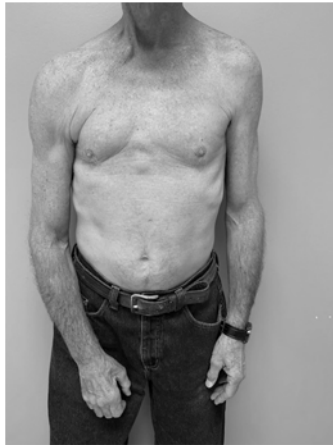Positioning

- Orthoses and positional aids are integral in maintaining a proper length-tension relationship following BPI
 - Functional
 - Positional
 - Sleep

(*Q10)

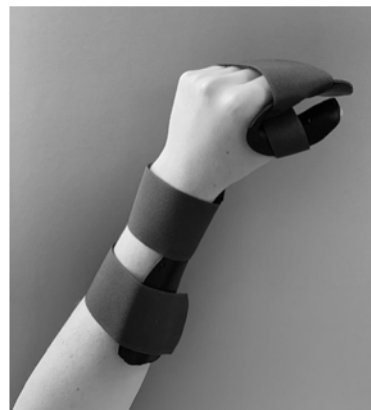
continued

Positioning, continued



continued

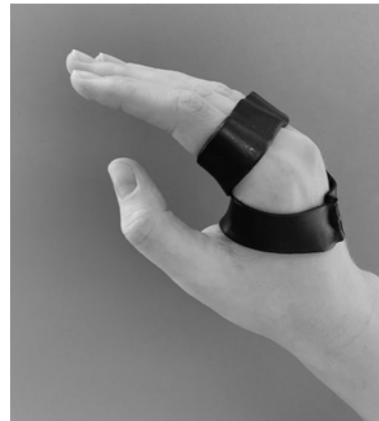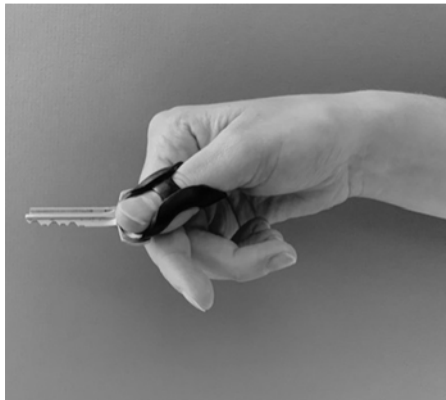
Positioning, continued



continued

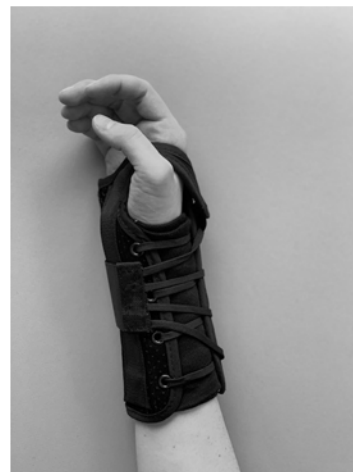continued

Positioning, continued



continued

Positioning, continued



continued

continued

Discussion

“To someone who has nothing, a little is a lot”
--Sterling Bunnell

continued

References:

- In a separate handout

continued[®]

Questions?

Anna.Vanvoorhis@gmail.com

continued[®]